

Intratympanic Steroid Treatment of Inner Ear Disease and Tinnitus (Preliminary Report)

Herbert Silverstein, MD^a
Daniel Choo, MD^a
Seth I. Rosenberg, MD^a
Jeffery Kuhn, MD^a

Sarasota, Florida

Michael Seidman, MD^b
Ira Stein, MD^b

W. Bloomfield, Michigan

Introduction

Systemic glucocorticoids, such as prednisone and dexamethasone, are known to improve hearing in certain cases of Meniere's disease, and autoimmune inner ear disease, as well as sudden sensorineural deafness.^{1,2} If steroids could be delivered directly into the inner ear through the round window membrane, higher concentrations could be achieved and the systemic side effects could be avoided.

Numerous animal and clinical studies have demonstrated that medications (such as gentamicin, streptomycin and lidocaine) can readily diffuse through the round window membrane.³ In addition, more than 30 years of clinical experience with steroid-antibiotic soaked Gelfoam during tympanoplasty surgery has shown that the middle ear (and, in turn, the inner ear) tolerates steroid medication without deleterious effect.

The purpose of this report is first, to describe techniques of applying steroids to the round window membrane in humans and to describe their effect on cochlear function in patients with various inner ear diseases (i.e., Meniere's

disease, autoimmune inner ear disease, sudden deafness, idiopathic sensorineural hearing loss and tinnitus), and second, to present data from an animal model of cochlear blood flow changes after applying dexamethasone to the round window membrane.

Methods

Humans

Forty-six patients with various types of inner ear disease were treated with intratympanic steroids (Table 1). Different methods of administration were employed to determine the most effective and practical way to deliver steroids to the round window membrane. The first technique was used in

Table 1. Diagnoses — Patients Treated with Intratympanic Steroids.

Diagnosis	#
Meniere's disease (unilateral)	19
Meniere's disease (bilateral)	3
Autoimmune inner ear disease	5
Sudden deafness	8
Progressive SNHL	2
Tinnitus & SNHL	7
Other	2
TOTAL	46

SNHL=Sensorineural hearing loss.

^aEar Research Foundation, 1901 Floyd Street, Sarasota, Florida.

^bHenry Ford Hospital, Department of Otolaryngology, W. Bloomfield, Michigan.

Presented at the One-Hundred-Twenty-Eighth Annual Meeting of the American Otological Society, Inc., Palm Desert, California, April 19, 1995.

Supported in part by grants from the Ear Research Foundation, Inc., Sarasota, Florida.

Reprint requests to: Herbert Silverstein, MD, Ear Research Foundation, 1901 Floyd Street, Sarasota, FL 34239; Phone: 813/366-1148; Fax: 813/366-8422.

17 patients. A tuberculin syringe (27 gauge needle, 1.5 inches long) was used to inject 0.2 to 0.3 cc of Depo-Medrol® (methylprednisolone acetate suspension 80 mg/cc) into the middle ear through an intact tympanic membrane just posterior to the umbo of the malleus. Patients were asked to remain in the supine position with their head turned to the side for 30 minutes. Most patients received two or more injections of the drug.

In order to allow patients to perform self-therapy at home with steroids, either a wick or a pressure equalizing tube was placed over the round window niche through a myringotomy incision. The wick was made by cutting a Merocel® sponge to 1 mm x 10 mm. The silicone Shepard ventilation tube (Smith & Nephew Richards) with an inner diameter of 1 mm was used. Patients were instructed to instill dexamethasone ophthalmic solution 1 mg/cc, two drops, three times a day into the ear and to massage the tragus to help deliver the medication into the middle ear. To prevent infection, Vasocidin® ophthalmic solution (prednisolone and sulfacetamide sodium) was used at bedtime.

A technique was devised to reduce the variables of inconsistent drug administration and/or anatomical obstruction of the round window membrane by mucosal bands and/or bone. Laser-assisted tympanostomy with middle ear endoscopy was used to evaluate the round window niche and to remove mucosal bands.⁴ The tympanic membrane was anesthetized with a topical solution of tetracaine base powder (160 mg) dissolved in .2 cc of isopropyl alcohol applied for eight minutes.⁵ This anesthetic effect lasts for two hours. The tetracaine solution was irrigated out of the external auditory canal with sterile water. When a speculum holder was used, the external auditory canal was injected with 1 to 2 cc of 1% Xylocaine and Adrenalin 1:100,000. A Sharplan CO₂ laser (model 1030) with a microslad attached to a Zeiss Opmi I microscope was then used to create a tympanostomy 2 mm in diameter, posterior to the umbo over the round window niche.⁶ Laser settings used were 1 or 2 watts at 0.1 second with a focused beam. After creating a .5 mm opening, wet Gelfoam was placed beneath the tympanic membrane to prevent laser injury to the promontory of the cochlea as the tympanostomy was enlarged. Multiple laser bursts were used to vaporize the opening to 2 mm in diameter. Otoendoscopes (Smith & Nephew Richards), 1.7 mm diameter, 0° and 30°, 10 mm length, were used to evaluate the middle ear anatomy and the round window niche. If mucosal bands were present, they were removed with small otological picks. Video and photo documentation

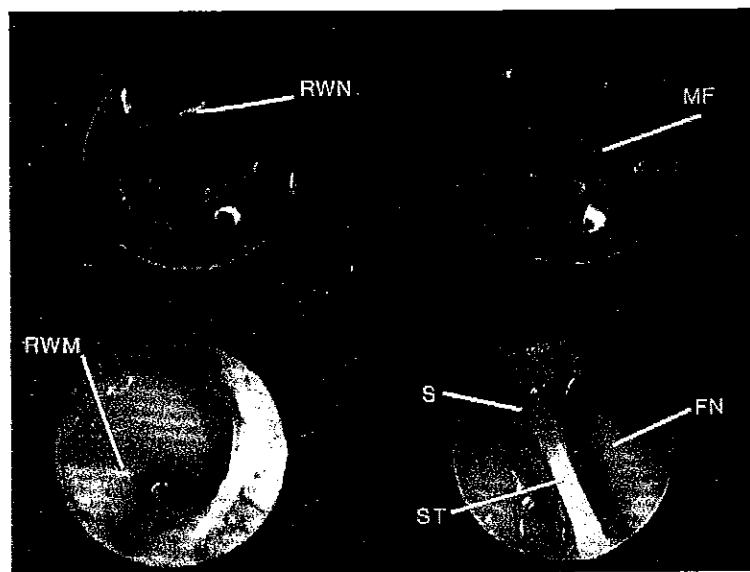


Figure 1. Video print taken during middle ear exploration using 1.7 mm endoscope 0° and 30°. Mucosal folds (MF) over the round window membrane (RWM) have been removed with small otological picks. Also visible are the round window niche (RWN), stapedial tendon (ST), and the facial nerve (FN).

of the procedure and middle ear anatomy was performed by attaching the Olympus camera (OTV-S4) to the endoscope and observing a 13-inch Olympus (OIV-141) color video monitor. Video prints were taken with a Sony color video printer (UP-1200) and the procedure was recorded with a 1/2" Sony Super VHS recorder (SVO-9500MD-VR-1B) (Figure 1). Small pieces of dry Gelfoam placed in the round window niche filled the middle ear space up to the tympanic membrane. A stainless steel Venturi Bobbin tube (TreBay Medical Corp.) with a 1.27 mm inner diameter was placed in the tympanostomy opening (Figure 2). This tube is designed to allow solution to flow easily through the opening into the middle ear. On Monday, Wednesday and Friday for three to four weeks, dexamethasone intravenous solution (0.2-0.3 ml, 4 mg/cc) was injected through the vent tube onto the Gelfoam. During the treatment period, patients were given Vasocidin ophthalmic solution to use before bedtime. The pressure equalizing tubes were removed after termination of treatment.

Animal

The experimental protocol was approved by the Henry Ford Hospital Care for Experimental Animals Committee in accordance with the National Institutes of Health (NIH) guidelines for humane animal use.

Fifteen male Hartley guinea pigs (250-300 grams) were used for the following studies. Animals were maintained at 22°C in group cages under a 12:12 hour light/dark cycle

beginning at 07:00 hours. Food and water were available ad libitum. All subjects were anesthetized with ketamine and Xylazine (100:1, 1 mg/kg). Core body temperature was maintained at 38°C +/- 1° using a heating blanket and monitored with a rectal probe. A midline neck incision was made and the animals were tracheotomized. The left carotid artery was cannulated for continuous heart rate and blood pressure measurements. The right bulla was opened and a silver ball (40 gauge) round window electrode was secured with dental cement. An Ag/AgCl reference electrode was placed in the neck musculature. The gross response from the round window electrode was led to a P511 Grass amplifier, gain x 5,000 (band pass of 0.3 to 3.0 kHz) and then to a signal processing board (Spectrum, Model TMS320C25). The averaged waveforms were stored on a 486 PC computer for off-line analysis. A total of 512 samples, 25us bin width, 256 responses were averaged. Tone bursts (1.0 ms. rise-fall time, 15 ms duration) ranged in frequency from 2.0 to 40 kHz.

Cochlear blood flow (CBF) was recorded using laser doppler flowmetry (Laser Blood Flow Perfusion Monitor BPM 403 TSI). With the bulla exposed, the second turn of the cochlea was prepared by removing the superficial mucosal layer. The laser doppler probe (0.8 mm) was sparingly covered with petroleum Vaseline to improve coupling and was then placed just over the second turn of the cochlea. Baseline blood flow measurements were obtained for 15 minutes, then either a control (NaCl vehicle) or dexamethasone ophthalmic 1 mg/cc (5ul) was placed on the round window while CBF was recorded for

two subsequent hours. Blood pressure and heart rate were stable throughout the procedure.

Selection of Patients

A total of 46 patients were treated with intratympanic steroids; 39 patients with unilateral or bilateral Meniere's disease, autoimmune inner ear disease, progressive or sudden sensorineural hearing loss, and seven patients with tinnitus and bilateral sensorineural hearing loss. In most patients, hearing loss had been chronic and not responsive to any conventional treatment. Table 2 shows the drug and the route used to deliver steroids to the inner ear.

Table 2. Intratympanic Steroids — Drug and Route.

Drug	Route	#
Depo-Medrol® 80 mg/cc*	Transtympanic injection	9
Decadron® ophthalmic solution 1 mg/cc**	Self-treatment — wick or PE tube	11
Depo-Medrol® and Decadron® ophthalmic solution	Transtympanic injection and self-treatment	8
Dexamethasone injection 4 mg/cc	Injection through vent. & Gelfoam	18
TOTAL		46

*Methylprednisolone succinate
**Dexamethasone

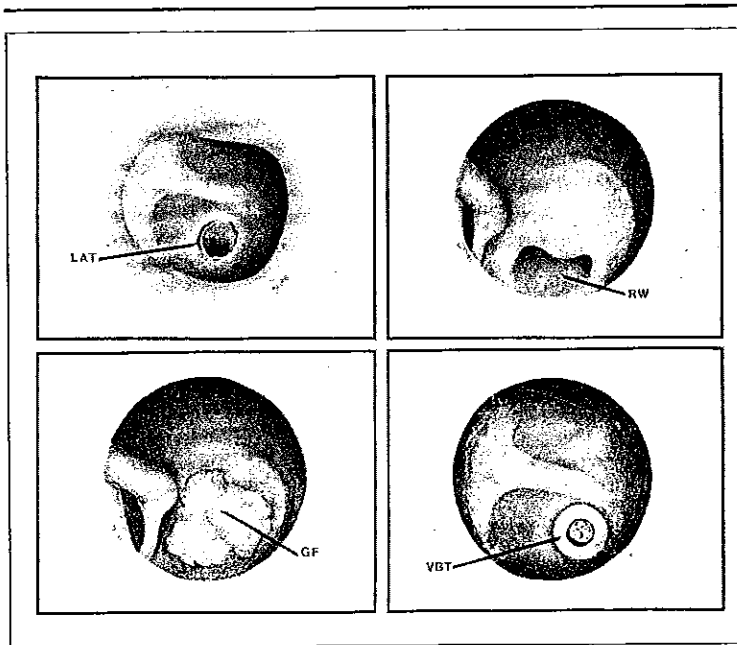


Figure 2. Laser assisted tympanostomy (LAT) and otoendoscopy. Gelfoam (GF) packed into round window (RW) niche. Venturi Bobbin tube (VBT) (Tre-Bay, St. Petersburg, FL) placed intratympanically.

Method of Evaluation

Audiometric testing, speech discrimination and tympanometry were performed prior to, during and after the treatment with intratympanic steroids. The criteria for significant changes in hearing was 10 dB speech reception threshold (SRT) or greater, or 15% speech discrimination (SD). Patients were asked to complete a tinnitus questionnaire before, during and af-

ter treatment (Figures 3A and 3B). A subjective analysis of tinnitus intensity was obtained by having patients rate their tinnitus from 0 to 10, with 10 being the loudest. Responses were either "improved," "unchanged," or "worse." Treatment was usually continued for one month and, if possible, the patients were evaluated on a weekly basis, or more often if they were receiving injections in the office. Patients with changes in tinnitus and hearing were followed with hearing tests and questionnaires at three, six and 12 months. If they did not respond, they were contacted by phone.

Results

Human

Twenty-one right ears and 25 left ears were treated with intratympanic steroids. There was no statistical difference in the results between the group initially treated with intratympanic injections of Depo-Medrol® and the group treated with dexamethasone, such that both methods of administration will be evaluated as one group.

Most patients tolerated the intratympanic steroid treatment well. Four of the 46 patients stopped the treatment early because of unwillingness to proceed. There were no complications of infection or severe hearing loss. Until the perforation healed, some patients experienced a 5 to 10 dB conductive hearing loss. In patients treated with a Merocel wick, perforations of the tympanic membrane appeared to heal slowly.

Seven patients with tinnitus as their main complaint were evaluated separately from the patients with various inner ear diseases. Regardless of the diagnosis, 15 of the 37 patients (41%) who had follow-up audiograms had improved hearing. Nine of these patients with improved hearing (60%) had Meniere's disease. The average SRT improvement was 15 dB and the average SD improvement was 24%. Three patients (8%) experienced worsening of hearing (average 11 dB SRT) during treatment (Tables 3, 4 and 5). No patient showed a decrease in SD score.

Of the 32 patients with tinnitus and inner ear disease who completed treatment, 15 (47%) had improvement in their symptoms. On a subjective scale of 1 to 10, the average improvement was 4 (Tables 6 and 7). Nine of the 15 patients (60%) who had improvement in tinnitus had Meniere's disease. Tinnitus re-

INITIAL TINNITUS QUESTIONNAIRE

NAME _____ DATE _____

1. How long have you had tinnitus?
 - a. less than 6 months
 - b. 6 months to 1 year
 - c. 1 to 2 years
 - d. 2 to 5 years
 - e. more than 5 years
2. Which ear is affected by the tinnitus?
 - _____ right ear
 - _____ left ear
 - _____ both ears
 - _____ cannot determine
3. Please grade the severity of the tinnitus: (circle the appropriate number)

1	2	3	4	5	6	7	8	9	10	
mild							moderate			severe
4. Do you have an associated hearing loss? If yes, which ear?
 - _____ right ear
 - _____ left ear
 - _____ both ears
5. Please circle the sounds that describe your tinnitus.
 - a. ringing
 - b. roaring
 - c. whistle
 - d. hissing
 - e. rushing
 - f. pulsing (heartbeat)
 - g. crickets
 - h. other
6. Please circle any items that apply to you.
 - a. history of exposure to loud noises (machinery, music, etc.)
 - b. history of IV antibiotics
 - c. history of head trauma (concussion, car accident, falls)
 - d. history of prior ear surgery
 - e. history of Meniere's disease
7. Please indicate if you have ever been treated for tinnitus prior to being seen here? _____

Figure 3A. Initial Patient Tinnitus Questionnaire.

FOLLOW-UP TINNITUS QUESTIONNAIRE

NAME _____ DATE _____

TREATMENT NUMBER _____

1. Please grade the severity of the tinnitus: (circle the appropriate number)

1	2	3	4	5	6	7	8	9	10	
mild							moderate			severe
2. In your opinion, has the tinnitus:
 - a. relieved greatly _____
 - b. relieved moderately _____
 - c. relieved mildly _____
 - d. remained the same _____
 - e. worsened _____
3. Please indicate if the quality of the tinnitus has changed (i.e., is the type of sound different, or is there a different pitch to the tinnitus, etc.). _____
4. Please indicate any other new symptoms:
 - a. persistent ear pain or ache _____
 - b. persistent decrease in hearing _____
 - c. any new dizziness or imbalance _____
 - d. other (please describe) _____
5. Please feel free to list any other comments or observations: _____

Figure 3B. Follow-up Patient Tinnitus Questionnaire.

mained improved in 13 of 15 patients during the follow-up period (average 4.7 months).

Of the 21 patients with Meniere's disease and follow-up audiograms, nine (43%) had a hearing improvement in SRT or SD. Of the 20 patients with Meniere's disease and tinnitus, nine (45%) had improvement in tinnitus (Table 8).

In two patients who received transtympanic injections of Depo-Medrol®, vertigo was not controlled and surgery was eventually performed.

Table 3. Intratympanic Steroids — Results (37 Patients).

Hearing Improved — 15 Patients (41%)*		
SRT**	12 patients	15 dB (average)
SD**	6 patients	24% (average)
Hearing Worse — 3 Patients (8%)		
SRT	3 patients	11 dB (average)

*9 patients with Meniere's disease

**3 patients with both SRT and SD improvement

The results with respect to hearing and tinnitus in the patients with autoimmune inner ear disease and sudden deafness are shown in Tables 9 and 10.

In patients with a main complaint of bilateral sensorineural high-frequency hearing loss and tinnitus, the results obtained with dexamethasone (4 mg/cc) injected intratympanically through a ventilation tube three times a week were disappointing (Table 11). Only one of seven patients experienced improvement in tinnitus. Tinnitus was worse in three patients, hearing was worse in two, and three of the seven patients stopped the injections after two weeks because there was no improvement. In this group, intratympanic dexamethasone did not appear to be a beneficial treatment.

Animal Experiments

Data from five control animals showed no change in compound action potentials (CAP) or cochlear microphonic (CM) thresholds after administration of saline over the round window membrane. In five animals treated with Decadron® ophthalmic solution (1 mg/cc), there was minimal to no change in hearing sensitivities as

Table 4. Intratympanic Steroids — Hearing Improved—SRT >10 dB.

Case	Drug	Tinnitus Result	Pre Rx Tinn	Post Rx Tinn	Pre Rx SRT dB	Post Rx SRT dB	Pre Rx SD%	Post Rx SD%	Comments
2	Depo	I	5	2	65	45	40	56	Meniere's s/p CS
6	Depo	U	3	3	75	60	88	92	Meniere's event. had CS
7	Depo	I	10	5	70	60	52	62	Meniere's
12	Depo	U	4	4	45	35	80	84	Meniere's
13	Dex otic drops	I	8	4	60	40	60	68	Meniere's
19	Dex otic drops	U	7	6	110	85	0	0	Sudden deafness
21	Dex otic drops	I	7	3	100	85	0	0	Meniere's
24	dex otic drops	U	3	3	80	65	20	28	Progressive SNHL
25	Depo	I	5	3	50	30	40	72	Progressive SNHL
33	Dex injection	U	7	7	75	65	0	8	Sudden deafness
43	Dex injection	U	2	2	55	45	60	76	Meniere's
44	Dex injection	I	7	4	15	5	100	100	Meniere's

Average Improvement = 15 dB

Depo = Depo-Medrol® (methylprednisolone acetate)
 Dex otic = Dexamethasone ophthalmic solution 1 mg/cc
 Dex injection = Dexamethasone 4 mg/cc
 SNHL = Sensorineural hearing loss
 CS = Cochleosacculotomy

I = Improved
 U = Unchanged
 SRT = Speech reception threshold
 SD = Speech discrimination

Table 5. Intratympanic Steroids — Hearing Improved—SD >15%.

Case	Drug	Tinnitus Result	Duration Tinn	Pre Rx Tinn	Post Rx Tinn	Pre Rx SRT dB	Post Rx SRT dB	Pre Rx SD%	Post Rx SD%	Comments
2	Depo	I	>10 yrs.	5	2	65	45	40	56	Meniere's
8	Depo	-	-	-	-	65	60	32	52	AIED
20	Dex otic drops	I	>15 yrs.	8	3	85	85	0	40	Meniere's
26	Depo	I	2 yrs.	5	3	30	30	40	72	Progressive SNHL
29	Dex otic drops	U	5 mos.	3	3	60	60	36	56	Ramsey-Hunt
43	Dex injection	U	1 mo.	2	2	55	45	60	76	Meniere's

Average Improvement = 24%

Depo = Depo-Medrol® (methylprednisolone acetate)
 Dex otic = Dexamethasone ophthalmic solution 1 mg/cc
 Dex injection = Dexamethasone 4 mg/cc
 SNHL = Sensorineural hearing loss
 AIED = Autoimmune inner ear disease

I = Improved
 U = Unchanged
 SRT = Speech reception threshold
 SD = Speech discrimination

measured by changes in CAP or cochlear microphonics. Specifically, a shift of 0 to 10 dB (one frequency for one animal shifted by 15 dB) occurred at the treated frequencies (3, 6, 9, 12 and 18 kHz).

Cochlear blood flow results for the control animals revealed no change (0.9% NaCl). The results in animals treated with Decadron® ophthalmic solution applied to the round window demonstrated a steady increase in CBF from a baseline of approximately 5.0-6.0 to 9.0-10.0 (72% increase) over the two-hour period of the experiment. Return to baseline was not seen in any experiment. (Note: this is a flux measurement and there are no units.) Blood pressure, pulse and respiration remained constant during the experiment.

Discussion

Permeability of the Round Window

It is well known that many drugs and substances, when placed in the middle ear, diffuse through the round window into the inner ear fluids. Goycoolea has written an excellent summary on the subject.³

Techniques of Delivering Steroids to the Inner Ear

Injecting steroids into the middle ear without topical anesthesia, using a tuberculin syringe and a 27 gauge 1.5-inch needle, is a painless and easy technique. However, in order for the drug to remain against the round window membrane and diffuse into the inner ear fluids, the patient should lie supine for 30 minutes. During this time, swallowing may clear the medication from the middle ear. In some patients, either mucosal bands over the round window membrane or a narrow round window niche may

Table 6. Intratympanic Steroids — Results (32 Patients).

Tinnitus improved	15 (47%)*§
Tinnitus unchanged	16 (50%)
Tinnitus worse	1 (3%)

*9 (60%) — Meniere's disease
 §Average improvement 4/10 units

prevent the solution from reaching the inner ear fluids. Placing a Merocel® wick through a myringotomy onto the round window appeared to work well initially, however, after several weeks the Merocel® wick became hard and ceased to act as a sponge. After removing the Merocel® wick, perforations in the ear drum were slow to heal. This is probably due to the effect of steroids inhibiting the healing process. The use of the Merocel® wick was discontinued after five cases.

Middle ear exploration using laser-assisted tympanostomy and otoendoscopy to evaluate the round window niche prior to treatment with intratympanic medication appears to be a promising technique.⁶ The advantage of using the laser is that there is a bloodless opening through which the endoscope may be passed. After any mucosal adhesions or bands are removed with small otological picks, dry Gelfoam is packed into the round window niche. The Gelfoam saturated with dexamethasone presumably helps diffuse the steroids into the inner ear fluids through the round window mem-

INTRATYMPANIC STEROID TREATMENT OF INNER EAR DISEASE AND TINNITUS (PRELIMINARY REPORT)

brane. The tympanostomy is kept open by using the Venturi Bobbin tube. Injecting the steroids through the tube three times a week keeps the Gelfoam saturated with solution and allows evaluation of the ear for infection or tube extrusion. In an earlier study, Gelfoam was used in the round window niche to deliver Streptomycin to the inner ear.^{8,9} For the patients who live at a distance or cannot come to the office three times a week, self-treatment with dexamethasone ophthalmic solution (1 mg/cc, 2 drops three times per day in the ear canal) is used. Vasocidin ophthalmic is given at night to prevent infection. In contrast to patients in the earlier study who used streptomycin solution, no patient developed otorrhea or middle ear infection during treatment with intratympanic steroids.^{8,9}

The self-treatment of inner ear disease with medication (i.e., steroids) placed in the external auditory canal is an appealing idea which is not only safer for the patient, but also averts the possible systemic effects of the medication when taken orally. The difficulties in self-treatment with otic drops include some uncertainty about whether the medication is getting into the middle ear space through the ventilation tube, and whether it remains near the round window long enough to allow diffusion into the inner ear fluids. Because of its bevelled inner opening, the Venturi Bobbin tube allows fluid to flow easily through its opening and may help deliver medication to the inner ear.

Corticosteroids

The first drug used in the study was methylprednisolone

Table 7. Intratympanic Steroids — Tinnitus Improved.

Case	Drug	Duration Tinn Pre Rx	Duration Tinn Relief & F/U	Pre Rx Tinn	Post Rx Tinn	Pre Rx SRT dB	Post Rx SRT dB	Pre Rx SD%	Post Rx SD%	Dx/Notes
2	Depo	>10 yrs.	9 mos.	5	2	65	45	56	40	Meniere's s/p CS
3	Depo	<1 mo.	8 mos.	6	0	50	45	20	28	AIED
5	Depo	>5 yrs.	9 mos.	8	2	45	45	76	72	AIED
7	Depo	>15 yrs.	9 mos.	10	5	70	60	52	62	Meniere's
13	Dex otic drops	9 mos.	8 mos.	8	4	60	40	60	68	Meniere's
15	Dex otic drops	3 mos.	5 mos.	5	0	60	65	80	80	Meniere's
20	Dex otic drops	>15 yrs.	4 mos. now fluct.	8	3	85	85	0	40	Meniere's
21	Dex otic drops	>20 yrs.	2 mos.	7	3	100	85	0	0	Meniere's
22	Dex otic drops	<2 wks.	2-3 mos.	4	0	60	56	60	64	Sudden deafness
25	Dex otic drops	1.5 mos.	2 mos. some fluct.	7	4	35	35	92	88	Meniere's
26	Depo	2 yrs.	6 mos.	5	3	50	30	40	72	Progressive SNHL*
30	Dex otic drops	9 mos.	3 mos.	7	3 (now 0)	45	45	66	80	Meniere's
31	Dex otic drops	>20 yrs.	1 mo.	6	2	85	85	0	4	SNHL & Tinnitus
38	Dex injection	<1 yr.	2 mos. some fluct.	9.5	6.5	65	75	60	60	Sudden deafness
44	Dex injection	6 mos.	1 mo.	7	4	15	5	100	100	Meniere's

Average follow-up = 4.7 months

Average Improvement = 4

*See Figure 6

Depo = Depo-Medrol® (methylprednisolone acetate)
 Dex otic = Dexamethasone ophthalmic solution 1 mg/cc
 Dex injection = Dexamethasone 4 mg/cc
 SNHL = Sensorineural hearing loss

AIED = Autoimmune inner ear disease
 CS = Cochleosacculotomy
 SRT = Speech reception threshold
 SD = Speech discrimination

Table 8. Intratympanic Steroids — Meniere's Disease.

Case	Drug	Tinnitus Result	Duration Tinn	Pre Rx Tinn	Post Rx Tinn	Pre Rx SRT dB	Post Rx SRT dB	Pre Rx SD%	Post Rx SD%	Comments
2	Depo	I	>10 yrs.	5	2	65	45	56	40	s/p CS*
6	Depo	U	>1 yr.	3	3	75	60	88	92	Eventually CS**
7	Depo	I	>15 yrs.	10	5	70	60	52	62	Bilateral MD
9	Depo	No tinn	NA	NA	NA	70	65	18	20	Labyrinthectomy
10	Depo	No tinn	NA	NA	NA	30	40	76	76	
11	Depo	U	1 mo.	3	3	45	45	84	78	
12	Depo	U	3 wks.	4	4	45	45	80	84	Pt. stopped Rx
13	Dex otic drops	I	9 mos.	8	4	60	40	60	68	
14	Dex otic drops	U	1 yr.	4	4	50	50	84	76	s/p RRVN
15	Dex otic drops	I	3 mos.	5	0	60	65	80	80	Bilateral MD
16	Dex otic drops	U	>20 yrs.	3	3	45	50	86	80	s/p RRVN
20	Dex otic drops	I	>15 yrs.	8	3	85	85	CNT	40	Bilateral MD aural pressure
21	Dex otic drops	I	>20 yrs.	7	3	100	85	0	0	s/p Lat. Scc perfusion strepto
23	Dex otic drops	U	10 days	6	6	70	No F/U	37	No F/U	
25	Dex otic drops	I	1.5 mos.	7	4	35	35	92	88	
27	Dex otic drops	U	<1 mo.	9	8	70	75	22	24	Tinn for 2 hrs after each shot
28	Dex otic drops	U	>19 yrs.	7	7	55	60	60	60	
30	Dex otic drops	I	9 mos.	7	3	45	45	66	80	Less hyperacusis able to sleep
41	Dex injection	U	6 mos.	7	7	10	10	96	96	
43	Dex injection	U	1 mo.	2	2	55	45	60	76	
44	Dex injection	I	6 mos.	7	4	15	5	100	100	
46	Dex injection	U	10 yrs.	4	4	70	70	40	28	

*See Figure 5

**See Figure 4

Depo = Depo-Medrol® (methylprednisolone acetate)

Dex otic = Dexamethasone ophthalmic solution 1 mg/cc

Dex injection = Dexamethasone 4 mg/cc

SNHL = Sensorineural hearing loss

AIED = Autoimmune inner ear disease

CS = Cochleosacculotomy

MD = Meniere's disease

RRVN = Retrolabyrinthine-Retrosigmoid vestibular neurectomy

SCC = Semicircular canal

I = Improved

U = Unchanged

SRT = Speech reception threshold

SD = Speech discrimination

acetate (Depo-Medrol®), 80 mg/cc. Seventeen patients were injected with this drug through an intact tympanic membrane over the round window niche area. However, this method became logistically difficult because patients needed to remain in the supine position for 30 minutes after the injection. It became apparent that a tissue esterase was needed to activate long-acting Depo-Medrol®; thus, we decided to stop using it and to try a shorter-acting drug. The remaining patients were treated with either dexamethasone ophthalmic (1 mg/cc) at home or dexamethasone (4 mg/cc) for intravenous injection in the office.

Discussion

It appears that either dexamethasone or Depo-Medrol®, when placed in the middle ear, diffuses into the inner ear and produces an effect on the cochlea in certain patients. A surprising finding was the number of patients (15) who noticed improvement in their tinnitus after delivering steroids into the inner ear (47%). Nine of these patients (60%) had Meniere's disease. Tinnitus remained improved in 13 of 15 patients during the follow-up period (average 4.7 months). Fifteen of 37 patients (41%) had improved hearing (60% of this group had Meniere's

Table 9. Intratympanic Steroids — Autoimmune Inner Ear Disease (AIED).

Case	Drug	Tinnitus Result	Duration Tinn	Pre Rx Tinn	Post Rx Tinn	Pre Rx SRT dB	Post Rx SRT dB	Pre Rx SD%	Post Rx SD%
1	Depo/Dex otic	N/A	N/A	N/A	N/A	50	55	64	77
3	Depo	I	<1 mo.	6	0	50	45	20	28
4	Dex	U	<6 mos.	6	6	50	45	24	34
5	Depo	I	>5 yrs.	8	2	45	45	76	72
8	Depo/Dex otic	N/A	N/A	N/A	N/A	65	60	32	52

Depo = Depo-Medrol® (methylprednisolone acetate)
 Dex otic = Dexamethasone ophthalmic solution 1 mg/cc
 I = Improved
 U = Unchanged

SRT = Speech reception threshold
 SD = Speech discrimination
 N/A = No tinnitus

Table 10. Intratympanic Steroids — Sudden Deafness.

Case	Drug	Tinnitus Result	Duration Tinn	Pre Rx Tinn	Post Rx Tinn	Pre Rx SRT dB	Post Rx SRT dB	Pre Rx SD%	Post Rx SD%
17	Dex otic	U	>1 yr.	2	2	70	70	68	60
18	Depo	N/A	N/A	N/A	N/A	65	65	8	0
19	Dex otic	U	>15 mos.	7	6	110	85	0	0
22	Dex injection	I	<2 wks.	4	0	60	56	60	64
31	Dex injection	I	>20 yrs.	6	2	85	85	0	4
32	Dex injection	U	3-4 yrs.	6	5	80	90	0	0
33	Dex injection	U	6 yrs.	7	7	75	65	0	8
38	Dex injection	I	<1 yr.	9.5	6.5	65	75	60	60

Depo = Depo-Medrol® (methylprednisolone acetate)
 Dex otic = Dexamethasone ophthalmic solution 1 mg/cc
 Dex injection = Dexamethasone 4 mg/cc
 I = Improved

U = Unchanged
 SRT = Speech reception threshold
 SD = Speech discrimination
 N/A = No tinnitus

INTRATYMPANIC STEROID TREATMENT OF INNER EAR DISEASE AND TINNITUS (PRELIMINARY REPORT)

disease). The average gain in SRT was 15 dB and the average improvement in SD was 24%. Evaluating treatment results in Meniere's disease is difficult because of the natural history of fluctuating hearing loss, tinnitus and associated symptoms. The same may be true of autoimmune inner ear disease and perhaps sudden deafness (viral). The long-term effect of intratympanic steroid treatment is now being evaluated.

Itoh and Sakata treated patients with vertigo due to Meniere's disease or intralabyrinthine vertigo using intratympanic injections of 4% lidocaine and dexamethasone (2 mg/cc).¹⁰ Dexamethasone was injected for a total of four or five times at intervals of one or two weeks. They found that tinnitus was improved in 74% of Meniere's disease patients after intratympanic dexamethasone treatment, and hearing was improved in patients with "low tone deafness and a convex type of audiogram." The number of patients with improved hearing was not reported. "Vertigo responded well to treatment" in 80%. Only two of our patients were treated for the primary complaint of vertigo. Both of these patients with Meniere's disease did not respond to Depo-Medrol® injections and eventually underwent surgical treatment. When patients with Meniere's disease, autoimmune inner ear disease, and sudden deafness gave reports of improvement in tinnitus, the possibility of treating patients with tinnitus secondary to sensorineural hearing loss (i.e., presbycusis) appeared a possibility. After treating seven patients with tinnitus as their main

complaint and with no obvious inner ear disease, it quickly became apparent that intratympanic steroids were not an effective treatment, and they were discontinued.

Mechanism of Action

The mechanism of steroid action on the inner ear is open to speculation. Steroids may cause vasodilation with increased microvascular blood flow in the cochlea as shown in animal experiments. This study indicates that permeability of the round window by dexamethasone in the guinea pig results in a 72% increase in blood flow. These effects lasted the duration of the experiment (two hours). There was no significant decrease in cochlear compound action potentials or in microphonics during the experiment. Thus, dexamethasone does not appear ototoxic in the animal model. Steroids may produce either a reduction of endolymphatic hydrops, a reduction of inflammation, or a placebo or other unknown effects.

The optimal concentration and dose of the drug may not have been found as yet. In the future, a sustained release capsule placed against the round window membrane that would deliver steroids to the inner ear on a more predictable basis may be developed. More animal experiments are needed to study the effects of local application of steroids and other drugs to the round window membrane. A double-blind cross-over study is now in progress to evaluate the results of intratympanic dexamethasone treatment. These results will follow in a later report.

Table 11. Intratympanic Steroids — Tinnitus and SNHL.

Case	Follow-Up	Tinnitus Result	Pre Rx Tinn	Post Rx Tinn	Pre Rx SRT dB	Post Rx SRT dB	Pre Rx SD%	Post Rx SD%	Comments
34	7 mos.	U	8	8	15	30	92	88	
36	1 mo.	U	6	6	15	5	96	100	Pt. stopped Rx— 2 weeks
37	>10 yrs.	W	10	9	45	40	92	84	
39	3 yrs.	W	6	10	10	No f/u yet	100	No f/u yet	Pt. stopped Rx— 2 weeks
40	3 yrs.	U	7	7	35	25	96	92	
42	9 yrs.	W	9	9	35	45	80	88	Pt. stopped Rx— 2 weeks
45	1 yr.	I	8	3	15	20	96	96	

I = Improved
 U = Unchanged
 W = Worse
 SRT = Speech reception threshold
 SD = Speech discrimination

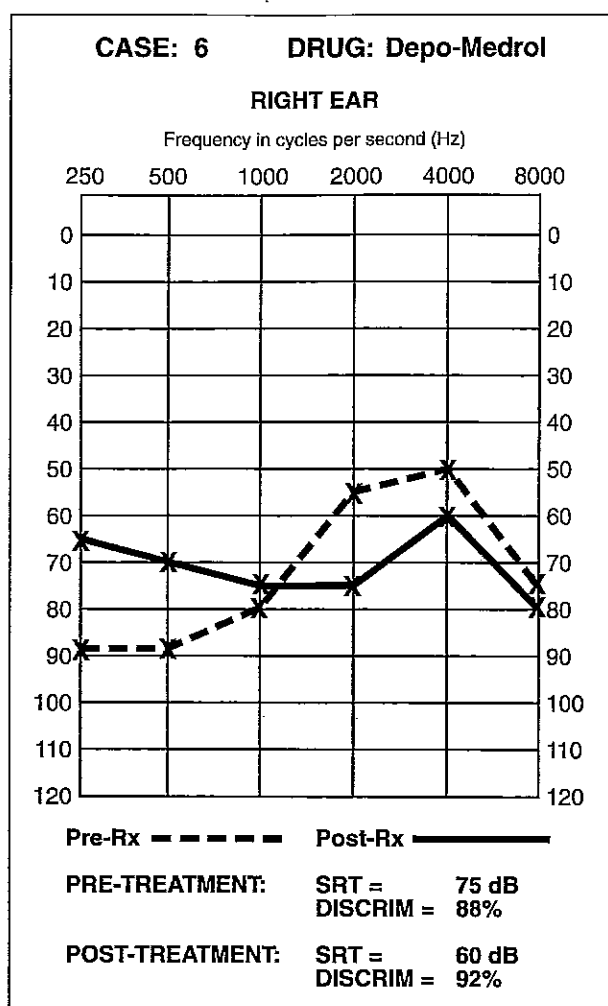


Figure 4. Case 6. 74-year-old, right ear, Meniere's disease and vertigo. SRT improved 15 dB after two intratympanic injections of Depo-Medrol®. Vertigo continued.

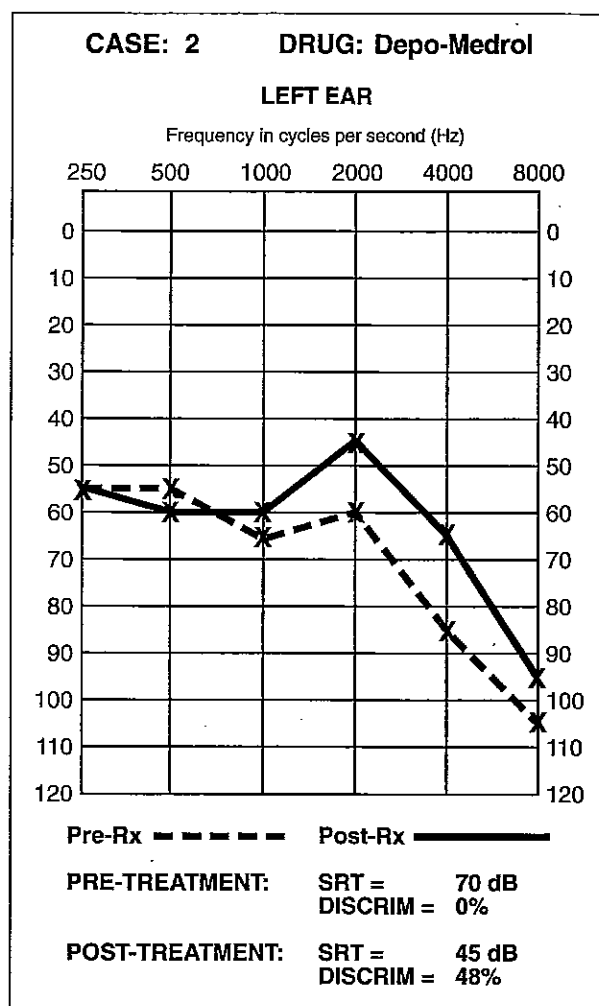


Figure 5. Case 2. 77-year-old, left ear, Meniere's disease 12 years after cochleosacculotomy. Vertigo, poor hearing and tinnitus. After intratympanic Depo-Medrol® injections (5) followed by self-treatment with dexamethasone ophthalmic (1 mg/cc) after myringotomy and Meroceel wick, tinnitus and hearing improved.

Summary

Intratympanic instillation of Depo-Medrol® (80 mg/cc), dexamethasone ophthalmic solution (1 mg/cc), or dexamethasone intravenous (4 mg/cc) solution produces improvement of cochlear function in certain patients with Meniere's disease, autoimmune inner ear disease and sudden sensorineural deafness. Tinnitus improved in 47%, most often in patients with Meniere's disease (9 of 15; 60%). The SRT improvement of greater than 10 dB or SD greater than 15% was documented in 41% (average improvement in SRT: 15 dB; SD: 24%). Patients with tinnitus and bilateral sensorineural hearing loss (i.e., presbycusis) did not benefit from the treatment.

Prior to treatment with intratympanic medication, laser-assisted tympanostomy with middle ear exploration, using otoendoscopy to determine the status of the round window niche and remove mucosal folds, helps in making the round window membrane accessible to local application of drops. Placing Gelfoam into the round window niche under direct vision, and using a Venturi Bobbin tube in the tympanic membrane, appears to be a satisfactory method for delivering medication to the inner ear fluids. The medication can be injected by the physician through the tube into the middle ear, or the patient can perform self-treatment at home, placing medication in the external auditory canal. A double-blind, cross-over study in patients with Meniere's disease is now in progress with

Institutional Review Board (IRB) approval, which will be reported at a later date.

This preliminary study has shown that intratympanic steroids may affect the symptoms of hearing loss and tinnitus in patients with various inner ear problems. Patients with Meniere's disease appear to respond in the highest percentage of cases. Hopefully, additional research will suggest the appropriate drugs which can be used to treat inner ear disease. Direct application of the drug to the round window membrane may increase the concentration in the inner ear fluids, thus avoiding the systemic effects.

Acknowledgment

The authors would like to acknowledge Sally May for the artistic illustration and Beth Lin for helping in editing this manuscript.

References

1. McCabe BF. Autoimmune sensorineural hearing loss. *Ann Otol Rhinol Laryngol* 1979; 88:585-9.
2. Wilson RW, Byl FM, Laird N. The efficacy of steroids in the treatment of idiopathic sudden sensorineural hearing loss. *Arch Otolaryngol* 1980; 106(12):772-6.

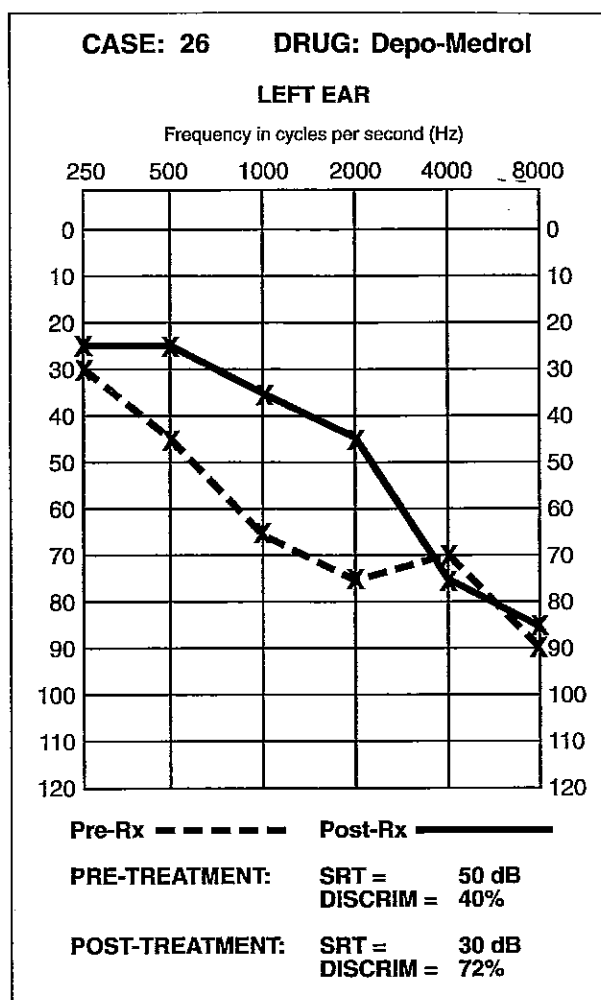


Figure 6. Case 26. 38-year-old, left ear, progressive sensorineural hearing loss. After two Depo-Medrol® injections, SRT improved 20 dB and SD improved from 40% to 72%.

3. Goycoolea MV. The round window membrane under normal and pathological conditions. *Acta Otolaryngol (Stockh)* 1992; (Suppl 49):343-45.
4. Silverstein H, Rowan T, Olds M, et al. Inner ear perfusion and the role of round window patency. Submitted.
5. Silverstein H, Call DL. Tetracaine base — an effective surface anesthetic for the tympanic membrane. *Arch Otolaryngol* 1969; 90:150-1.
6. Silverstein H, Krespi Y, Rosenberg S, et al. Laser-assisted tympanostomy. *Laryngoscope* 1996; 106(8).
7. Rosenberg S, Silverstein H, Willcox TO, et al. Endoscopy in otology and neurotology. *Am J Otol* 1994; 15(2):168-72.
8. Silverstein H, Hyman SM, Feldbaum J, et al. Use of streptomycin sulfate in the treatment of Meniere's disease. *Otolaryngol Head Neck Surg* 1984; 92(2):229-32.
9. Smouha E, Silverstein H, Jones R. Intratympanic and parenteral streptomycin therapy for Meniere's disease, in Nadol Jr. JB (ed): *Second International Symposium on Meniere's Disease*. Kugler & Ghedini Pub., June 1988; 451-8.
10. Itoh A, Sakata E. Treatment of vestibular disorders. *Acta Otolaryngologica* 1991; Suppl. 481:617-23.